

## PennHIP Report

Owner's Copy

Referring Veterinarian: Dr Jeffrey Ellis

Clinic Name: VCA Preston Park Animal Hospital

Email: vcaprestonpark@vca.com

Clinic Address: 18770 Preston Road  
Dallas, TX 75252

Phone: (972) 985-0081

Fax: (972) 758-0881

## Patient Information

Client: Baran, Michelle

Tattoo Num:

Patient Name: Marvel's Hero For Hire "Sable"  
GCH; CGC

Patient ID: 66259

Reg. Name: Marvel's Hero For Hire "Sable"  
GCH; CGC

Registration Num: SR99640701

PennHIP Num: 155530

Microchip Num: 956000010006397

Species: Canine

Breed: GERMAN SHORTHAIRED POINTER

Date of Birth: 14 Jul 2017

Age: 45 months

Sex: Male

Weight: 70 lbs/31.8 kgs

Date of Study: 14 Apr 2021

Date Submitted: 14 Apr 2021

Date of Report: 20 Apr 2021

## Findings

Distraction Index (DI): Right DI = 0.28, Left DI = 0.28.

Osteoarthritis (OA): **No radiographic evidence of OA for either hip.**

Cavitation/Other Findings: No cavitation present.

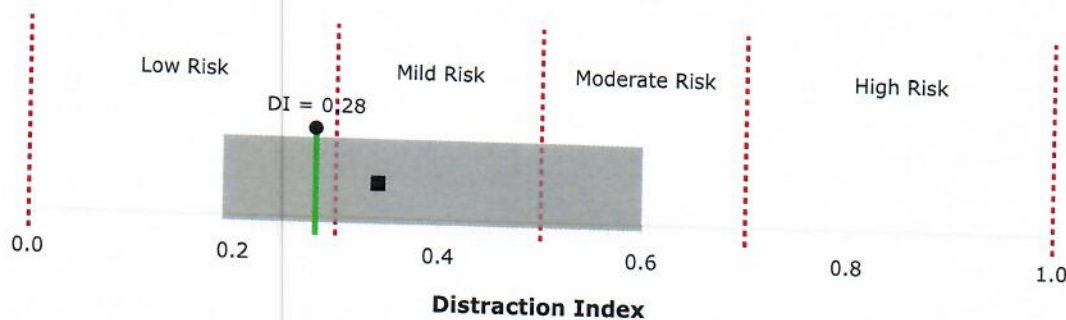
## Interpretation

Distraction Index (DI): The laxity ranking is based on the hip with the greater laxity (larger DI). In this case the DI used is 0.28.

OA Risk Category: The DI is less than or equal to 0.30. This patient is at minimal risk for hip OA.

Distraction Index Chart:

### GERMAN SHORTHAIRED POINTER



**BREED STATISTICS:** This interpretation is based on a cross-section of 1478 canine patients of the GERMAN SHORTHAIRED POINTER breed in the AIS PennHIP database. The gray strip represents the central 90% range of DIs (0.19 - 0.60) for the breed. The breed average DI is 0.34 (solid square). The patient DI is the solid circle (0.28).

**SUMMARY:** The degree of laxity (DI = 0.28) falls within the central 90% range of DIs for the breed. This amount of hip laxity places hip at a minimal risk to develop hip OA. **No radiographic evidence of OA for either hip.**